

Liver biopsy assessment in chronic viral hepatitis: a personal, practical approach

Neil D Theise^{1,2}

¹Department of Pathology, Beth Israel Medical Center of Albert Einstein College of Medicine, New York, NY, USA and ²Department of Medicine, Division of Digestive Diseases, Beth Israel Medical Center of Albert Einstein College of Medicine, New York, NY, USA

The terminology for assessment of chronic viral hepatitis in liver biopsy specimens has become confusing with the proliferation of grading and staging schemes that have paralleled the rise of the hepatitis C epidemic and the importance of mixed viral infections. This review represents a personal approach to the interpretation of these biopsy specimens, aiming at clarifying and simplifying the important points for the general pathologist confronted by these diagnostic dilemmas. The most commonly used schemes—Ishak modification of the Knodell ‘hepatic activity index’, Scheuer, Metavir, Batts–Ludwig classifications—are presented with evaluation of their pros and cons. Which scheme is selected is less important than the consistent use of a single scheme and the clear naming of that scheme in pathology reports. The importance and clinical implications of identifying severe necroinflammatory activity in the form of ‘confluent necrosis’ is discussed. Pathologists must also be clear about assessing concomitant diseases, in particular, alcoholic or non-alcoholic fatty liver disease, and be aware that grading/staging schemes for chronic hepatitis do not apply to mixed disease conditions. Other important features to be evaluated in all chronic hepatitis biopsy specimens include iron (which may represent hereditary hemochromatosis or secondary uptake) and neoplasia-associated changes, namely large cell change and small cell change; these findings and their clinical import are updated and reviewed. Sample approaches to composing useful diagnostic reports are also presented.

Modern Pathology (2007) 20, S3–S14. doi:10.1038/modpathol.3800693

Keywords: grading; staging; chronic hepatitis; viral hepatitis; liver biopsy

Once upon a time, the assessment of liver biopsy specimens from patients with chronic viral hepatitis was very simple. There were three categories created for us by the Gnomes (not fairytale, mythical, woodland folk, but ‘an International Working Group’ of liver pathologists): chronic persistent, active, and lobular hepatitis (CPH, CAH, and CLH, respectively).¹ In addition, one would describe the scarring and the progression toward cirrhosis. These categories were sufficient because there were only three likely diseases to be dealt with: autoimmune hepatitis, hepatitis B, and non-A-non-B hepatitis. For the first two, these categories of histopathology were reasonably prognostic. Also, only autoimmune hepatitis had a treatment, which was immune suppression. As for non-A, non-B hepatitis, well... there wasn’t much to be said for that beyond describing the histologic changes, knowing that

CPH, CAH, and CLH were not predictive in those cases.

Then things changed. Hepatitis C was discovered and the true extent of the epidemic was made clear. Antiviral treatments were developed that required assessments in clinical trials and detailed comparison between pre- and post-treatment biopsies. Continuing intravenous drug use in urban centers made mixed viral infections more common. Most liver biopsies were not performed for autoimmune or hepatitis B anymore, but rather were for a steady stream of hepatitis C patients and patients with mixed viral infections (hepatotropic viruses with or without HIV). Suddenly, the gift to Hepatology bequeathed by the Gnomes was no longer of use and something new had to take its place.^{2,3}

Thus, it was that descriptive terminology, quantitatively, or semi-quantitatively ‘grading’ necroinflammatory activity and ‘staging’ scarring and architectural distortion, that is progression toward cirrhosis, became the dominant trend. The same features that were recognized in the original Gnomes’ descriptions remained unchanged, but were now simply described (in greater detail) rather

Correspondence: Dr ND Theise, MD, Department of Medicine, Division of Digestive Diseases, Beth Israel Medical Center, First Avenue at 16th Street, New York, NY 10003, USA.
E-mail: ntheise@chpnet.org
Received 14 July 2006; accepted 26 July 2006

than used to suggest prognosis. The Gnomes were at the forefront of this reconsideration, but many others also joined in. All were agreed that a new system was needed, but none of the proposed systems rose to the fore as the selection of a community consensus.

This abundance of choices coupled with the hepatitis C epidemic has proved to be tremendously confusing to the general surgical pathologist. For them, liver biopsies had once been occasional problems and there was a satisfyingly simple classification. But how to make sense of all the new options and directives from a multitude of experts to deal with an increasing rate of liver specimens from the huge reservoir of patients with hepatitis C infections? The Gnomes' gentle woodland has become something of a 'scoring jungle'.⁴

The goal of this paper is, in short, to allay the anxiety caused by this situation for the general pathologist by setting forth some basic principles for assessment of liver biopsy specimens from chronic hepatitis patients. There will be elements of review, of course, but this will not be academically complete; such papers have already been published by a number of wise and skilled hepatopathologists.^{5–11} Instead, this paper will briefly describe the histopathologic features of note, some pros and cons of the different grading/staging systems, and the extra things that one must look out for to know that one has confidently squeezed every bit of clinically important information out of every biopsy.

Grading and staging systems galore

Stepping back from the simplicity of CPH vs CAH (and from the increasingly common, and not very predictive CLH) meant that a system for describing these changes needed to be developed. Knodell *et al* presented the first system to accomplish this systematically.¹² They described three categories of necroinflammatory activity to be semiquantitatively graded: periportal injury with or without bridging necrosis, lobular injury, and portal inflammation (Figure 1). A fourth category assessed stage of scarring and architectural distortion, ranging from portal fibrosis to cirrhosis. The numbers assigned to the different categories were then to be added together to yield an hepatic activity index (HAI).

This system was quickly seized upon for use in clinical trials and clinical–pathologic correlation studies as they provided numerical data that could be used for statistical analysis. However, it was quickly recognized that there was a flaw in this approach. The HAI combined the grading and staging into a single number, but these were entirely different categories of observation, which could not logically be combined. It became particularly evident at descriptive extremes: a biopsy with very little necroinflammatory activity, but with cirrhosis,

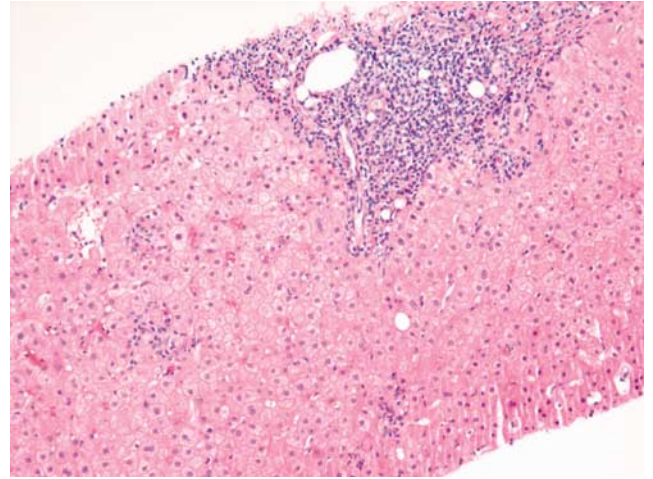


Figure 1 Necroinflammatory activity in chronic hepatitis. A 62-year-old woman with hepatitis C undergoes needle biopsy for grading and staging of her disease. A portal tract is expanded by a predominantly mononuclear cell infiltrate. Although the limiting plate is intact along most of its extent, there is interface hepatitis breaching it on the right-hand side, including inflammation and an acidophil body. Likewise, in foci of lobular hepatitis toward the left, inflammation is seen with and without acidophil bodies. (H&E, $\times 10$ original magnification).

might have the same numerical value as a biopsy specimen with moderate activity and early scarring. Same number, but clearly different disease states.

The Gnomes once again stepped in and offered what became widely known as the Ishak modification (Kamal Ishak, Gnome, was also senior author of the Knodell paper and became first author of the Gnomes' revision).¹⁰ The major changes with this approach were that the combined score was eliminated and that confluent necrosis, including bridging necrosis, was separated into a separate fourth category of necroinflammatory assessment; minor alterations in semiquantitative grading of activity were also introduced (Table 1).

Of course, once the doors to change were thus opened, other pathologists tried their hand at developing useful systems, often in response to specific clinical or research concerns, some particularly focused on the issue of reproducibility. The most widely used of these were developed by Peter Scheuer (Table 2), the French Metavir group (Table 3, Figure 2) and by Kenneth Batts and Jurgen Ludwig (Figures 3 and 4).^{13–15} The Scheuer and Batts–Ludwig systems aimed at greater simplicity compared to the extensive subcategories of Knodell and Ishak. The Metavir's approach was to identify, through extensive intraobserver variation studies, a simplified system that would be consistently reproducible without significant variation.

Here, I present my own thoughts about the benefits and drawbacks of each of these systems, after which I will suggest how the general pathologist can select an approach that makes sense for their own clinical practice.

Ishak

Pros: Great detail! This abundance of descriptive detail is extremely useful for performing clinical-pathologic research and for guiding the pathologist to take note of all aspects of viral injury. It has been

Table 1 Ishak modification for hepatic activity index (HAI) for scoring of necroinflammatory activity in chronic hepatitis

<i>(A) Periportal or periseptal interface hepatitis (piecemeal necrosis)</i>	
Absent	0
Mild (focal, few portal areas)	1
Mild/moderate (focal, most portal areas)	2
Moderate (continuous around <50% of tracts or septa)	3
Severe (continuous around >50% of tracts or septa)	4
<i>(B) Confluent necrosis</i>	
Absent	0
Focal confluent necrosis	1
Zone 3 necrosis in some areas	2
Zone 3 necrosis in most areas	3
Zone 3 necrosis+occasional portal-central (P-C) bridging	4
Zone 3 necrosis+multiple P-C bridging	5
Panacinar or multiacinar necrosis	6
<i>(C) Focal (spotty) lytic necrosis, apoptosis and focal inflammation</i>	
Absent	0
One focus or less per ×10 objective	1
Two to four foci per ×10 objective	2
Five to ten foci per ×10 objective	3
More than ten foci per ×10 objective	4
<i>(D) Portal inflammation</i>	
Absent	0
Mild, some or all portal areas	1
Moderate, some or all portal areas	2
Moderate/marked, all portal areas	3
Marked, all portal areas	4

shown to be fairly reproducible, although more so (as is true for most of the systems) in terms of staging than for grading. It also recognizes the importance of confluent necrosis as a separate category of injury. This is particularly important in that the presence of confluent necrosis, truly severe disease, has specific and quite important clinical implications. These will be discussed in detail below. Also, this system has a stage of ‘developing cirrhosis’, absent in

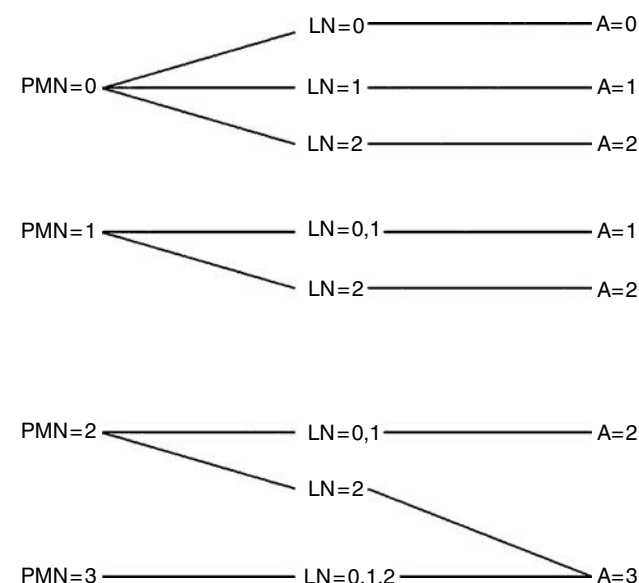


Figure 2 Metavir algorithm for the evaluation of histological activity. PMN, piecemeal necrosis; 0, none; 1, mild; 2, moderate; 3, severe; LN, lobular necrosis; 0, no or mild; 1, moderate; 2, severe; A, histological activity score; 0, none; 1, mild; 2, moderate; 3, severe.

Table 2 Scheuer classification for grading and staging of chronic hepatitis

Grade	Portal/perportal activity	Lobular activity
0	None	None
1	Portal inflammation	Inflammation but no necrosis
2	Mild piecemeal necrosis	Focal necrosis or acidophil bodies
3	Moderate piecemeal necrosis	Severe focal cell damage
4	Severe piecemeal necrosis	Damage includes bridging necrosis
Stage	Fibrosis	
0	None	
1	Enlarged, fibrotic portal tracts	
2	Periportal or portal-portal septa, but intact architecture	
3	Fibrosis with architectural distortion, but no obvious cirrhosis	
4	Probable or definite cirrhosis	

Table 3 Metavir classification for staging of hepatitis C liver disease

No scarring	0
Minimal scarring	1
Scarring has occurred and extends outside the areas in the liver that contains blood vessels	2
Bridging fibrosis is spreading and connecting to other areas that contain fibrosis	3
Cirrhosis or advanced scarring of the liver	4

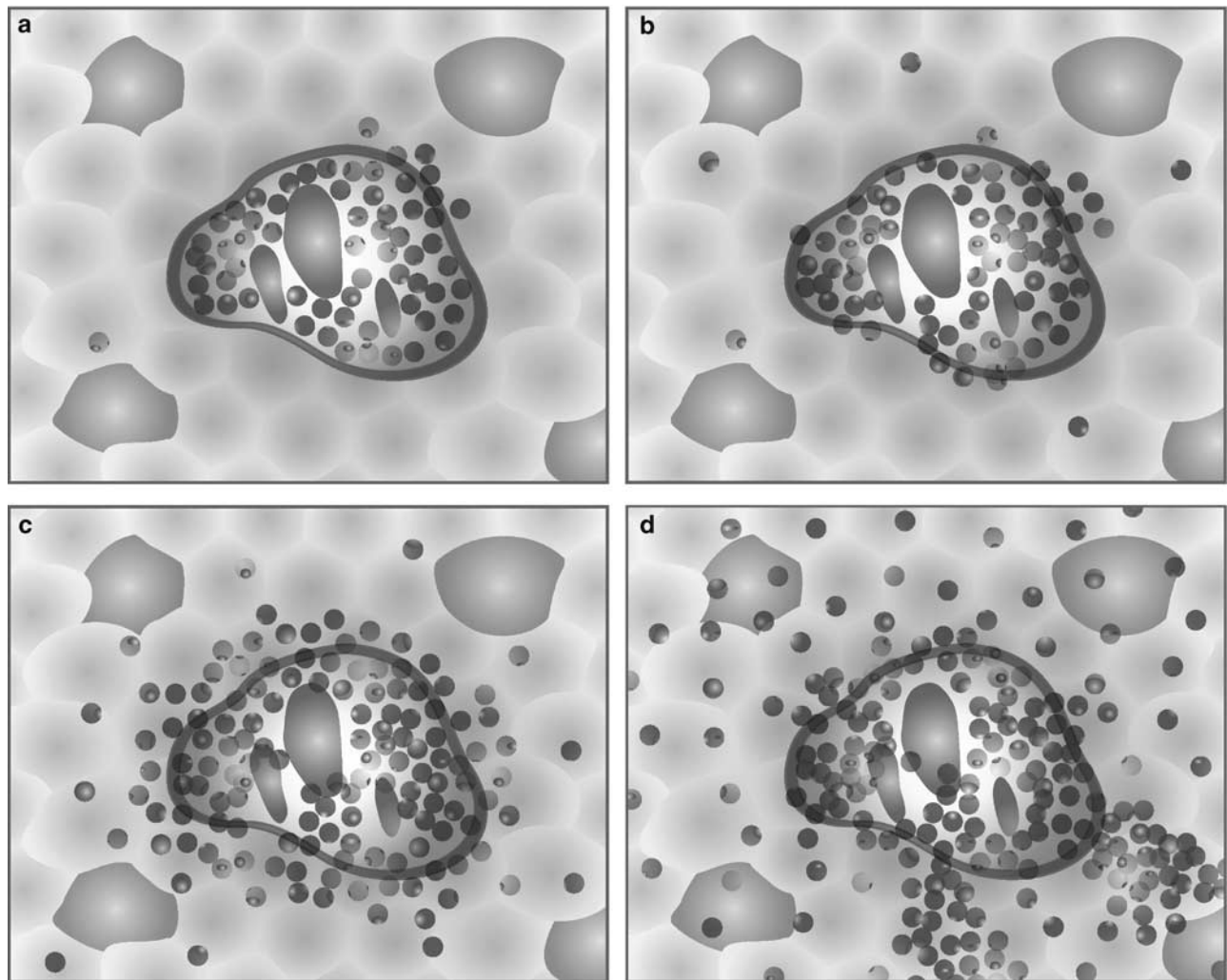


Figure 3 Batts–Ludwig diagrams of necroinflammatory activity. Note that all grades of activity contain portal inflammation; therefore, it is a defining feature of chronic hepatitis and not assessed separately from other necroinflammatory lesions. (a–c) Activity grades 1 through 3. Confluent necrosis, in the form of bridging necrosis, is present only in activity grade 4 (d). These versions adapted with permission from Batts KP, Ludwig J. Chronic hepatitis. An update on terminology and reporting. *Am J Surg Pathol* 1995;19:1409–1417.¹⁵

explicit form in the other systems. In some (Scheuer, Batts–Ludwig) the category exists, but the description is somewhat confusing (see below).

Cons: Too much detail! This amount of detail is not particularly useful for evaluation of an individual patient's biopsy specimen. The number of categories and the lack of clarity about the clinical significance of any of them means that the clinician will be inundated with data without obvious use. Also, while this detailed descriptive analysis can yield meaningful statistical data for large populations of patients or of biopsy specimens, variations for a single patient who has received two or more biopsies are difficult to distinguish from sampling error alone.

Another issue is that the category of portal inflammation is given its own weight. I believe this is inappropriate for a clinical evaluation as this is the defining lesion for chronic hepatitis (although it

of course can be mimicked by other conditions). Indeed, for the Gnomes, abundant mononuclear infiltrates of the portal tracts, even with lymphoid follicles, was originally considered inactive in the absence of interface or lobular hepatitis. Furthermore prominent lymphoid aggregates or follicles of hepatitis C might falsely inflate the severity of necroinflammatory activity compared to conditions where such lymphoid densities are much less typical (hepatitis B, autoimmune hepatitis).

Metavir

Pros: This system was developed by establishing criteria to be assessed by a panel of pathologists and then the descriptions were analyzed to identify the most consistently reproducible scoring. This approach is different than the other systems for which

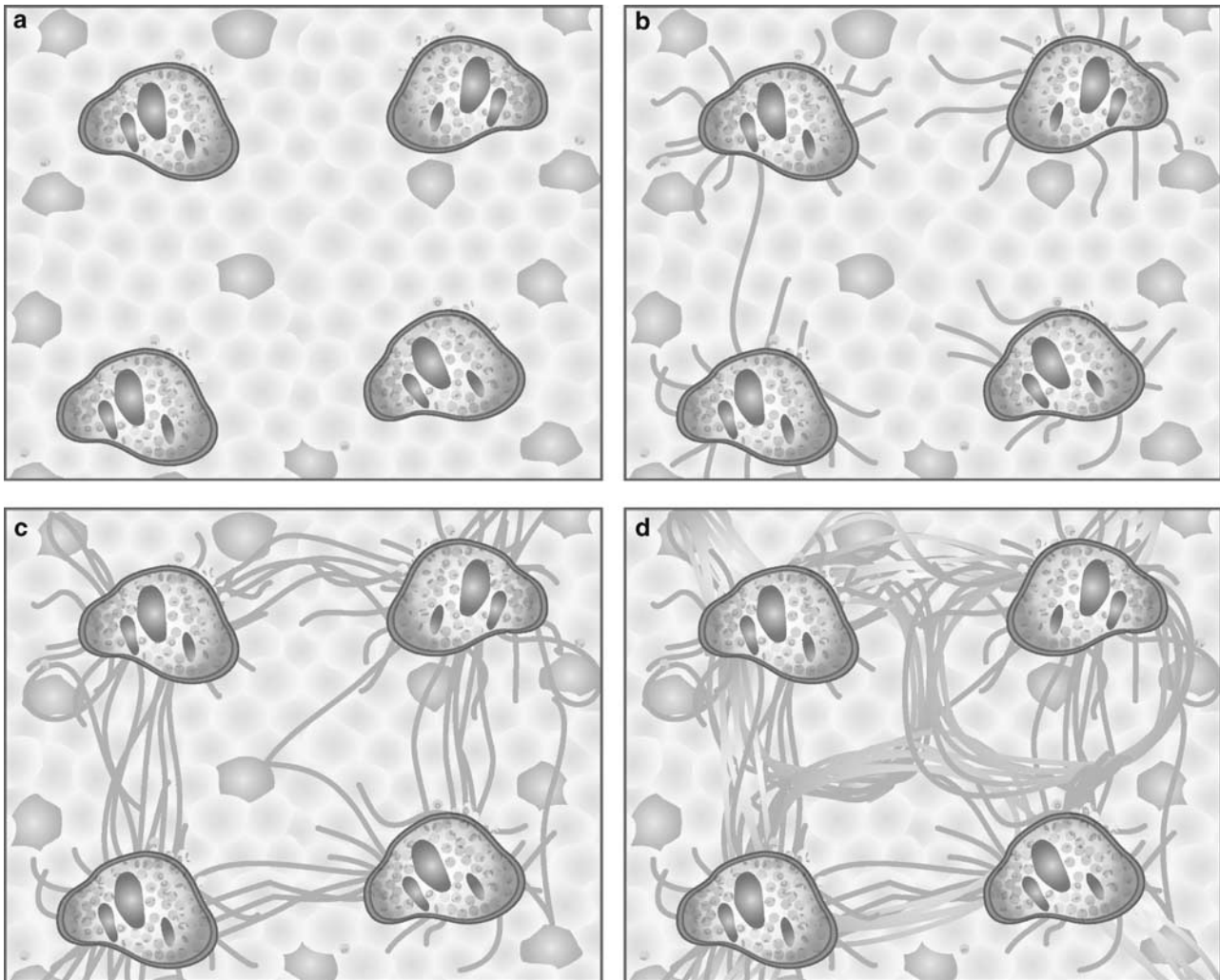


Figure 4 Batts-Ludwig diagrams of progression of scarring in chronic hepatitis. The panels portray stage of disease with (a) portal tract scarring, (b) fibrotic septa extending from portal tracts and focally linking them, (c) a transition to cirrhosis where some of the tissue shows regenerating nodularity completely bounded by scar, and (d) fully established cirrhosis. In a needle biopsy specimen, (c) may translate to a portion of the needle core with such nodularity, but other areas without this change. These versions adapted with permission from Batts KP, Ludwig J. Chronic hepatitis. An update on terminology and reporting. *Am J Surg Pathol* 1995;19:1409-1417.¹⁵

categories and scorings were created on the basis of the authors' knowledge (assumptions) of pathophysiology, which then underwent subsequent testing for reproducibility. The Metavir system is also relatively simple, yielding scores of mild, moderate or severe for activity and four stages of progression.

Cons: To arrive at those simple scores, the pathologist must evaluate separate criteria and then follow a chart to arrive at the final 'mild, moderate, or severe'. It is not intuitively obvious, at a glance, how to do so, however. Another difficulty is that there is a gap between stage 3, 'frequent fibrous septa' and stage 4, 'cirrhosis'. There is no category for a transition to or developing cirrhosis. Thus, if part of a specimen is nodular, but other parts are not, then one must suggest something like 'stage 3-4', thus creating an implicit fifth stage, which is not explicitly part of the system.

Scheuer

Pros: This system is also fairly simple, thus improving its reproducibility. Only two categories are presented for evaluation of activity: portal/periportal and lobular. It recognizes that the amount of portal inflammation is not particularly important as, in the absence of interface hepatitis, it is given a grade of 1 and is explicitly identified as coincident with the old 'chronic persistent hepatitis'.

Cons: While there is a stage of disease progression that probably corresponds to transition to cirrhosis, the phrase 'fibrosis with architectural distortion' but no obvious cirrhosis' is unclear in its intent. What is 'architectural distortion', particularly for a generalist not steeped in the details of liver anatomy as a focused academic hepatopathologist might be? Does 'no obvious cirrhosis' mean no nodularity at

all? Or that the specimen is only focally nodular so that one can not confirm fully developed cirrhosis? Knowing how Professor Scheuer discussed biopsy specimens at the microscope I do believe he intended this to be a category of 'transition to cirrhosis', of focal, not total nodularity. But the phrase remains unclear to those who only have the tables to interpret.

Batts-Ludwig

Pros: This system is simple and easily reproducible, like the Metavir and Scheuer systems. In particular, the pictures provided in the original paper (and reproduced more recently elsewhere),⁵ give a clear graphic demonstration of what is meant by each grade and stage of disease. Within a short time of using these figures as reference points, the general pathologist should be able to confront scoring of chronic hepatitis specimens with confidence. Moreover, the pictures are particularly useful for making clear to the clinician just what is meant by a verbal description or a staging score. The better the clinician can picture in their mind what is being conveyed by the pathologist report, indeed, imagine the visuals that the pathologist is converting into text, the more likely communication among pathologist, clinician, and patient will be effective.

Cons: As with the Scheuer classification, stage 3 is described as architectural distortion. The drawing makes clear, however, that the lesion consists of focal nodularity which is a help. However, the drawing is of a much broader region of liver tissue than is obtained by needle biopsy, so the applicability of the image becomes a matter of how the pathologist regarding the image translates it into a finding in a narrow biopsy specimen. The lack of clarity of the verbal description then contributes to possible confusion for the less experienced.

So what do I do?

Before I describe my own practice, let me make one important point that is perhaps the most important part of this paper and the most useful teaching for the generalist, so important it deserves to be typographically highlighted:

It does not matter which system you use.

'What? It doesn't matter?' so many general pathologists have responded when I say this. And I affirm: no, it does not matter. I have even informally discussed this with primary authors of all the different systems and none of them have disagreed. It is up to the pathologist working with the clinicians to figure out the needs of the clinician and to determine what is most comfortable and what makes sense. Providing words, not just the numbers, is what seems most important—the words provide a picture to the clinician (and to the patient) so that they have a dynamic sense of disease process, rather

than a stack of numbers to play with blithely and often inappropriately.

The second key point is also worthy of highlighting:

Name the system clearly in your diagnosis and communicate with your clinicians the meaning of the different scorings in that system.

If one does not include the name of the system then the numbers become meaningless. This is another reason to be verbally, as well as numerically, clear as to what is seen in the specimen. However, numbers are often more impressive to the clinician (or are perhaps the only thing read by them). For example, Metavir stage 3 of 4 is frequent fibrous septa, Scheuer and Batts-Ludwig stage 3 of 4 is extensive fibrosis with architectural distortion, Ishak stage 3 of 6 is widespread portal fibrosis with focal septa.

This is particularly important to note as patients often do not remain with one hepatologist/gastroenterologist when faced with ambiguous decision making about treatment, or when they move during the long course of their disease and have to find new clinicians who may only have the old biopsy report for assessment. The clinicians you serve may understand your numbers, but the clinicians and/or pathologists that patients are likely to encounter elsewhere, at another time, may not understand your scores unless you name the system used.

What I Do for Grading of Necroinflammatory Activity

The degree of activity in most specimens is not actually used as much of a guide for treatment. Assessing it in detail for research purposes is of great import and for research purposes I use the Ishak system because of its ample detail. But day to day, this detail, as I noted, would be more confusing than helpful and does not, in the 'real world' play much of a role in treatment decisions *except* when it is particularly severe. By severe, I mean confluent necrosis, very much as described in the Ishak staging: from perivenular hepatocyte dropout (Figure 5) to bridging necrosis (Figure 6) to parenchymal collapse. Confluent necrosis of any degree in a hepatitis B or hepatitis C biopsy implies specific clinical events or conditions that have possibly important clinical correlates requiring attention.¹⁶

In hepatitis C, confluent necrosis may simply reflect an acute flare of activity in this typically waxing and waning disease. However, given the epidemic nature of the disease, some patients with hepatitis C will inevitably also have other concomitant conditions requiring evaluation and perhaps treatment. Thus, confluent necrosis may indicate acute coinfection with another hepatotropic virus (acute hepatitis A or B), concomitant autoimmune hepatitis, or superimposed drug/toxin mediated injury. There is also the possibility of immunocompromise in a patient with hepatitis C, iatrogenic (for

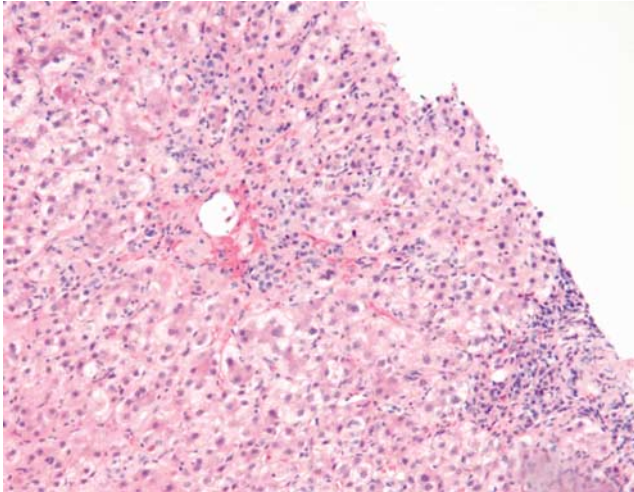


Figure 5 Confluent necrosis (perivenular). The hepatocytes around the central vein toward the upper left have all been lost, replaced by pigment-laden macrophages (silver to grey, would be prominent magenta on PAS-D stain) and mononuclear cells (H&E, original magnification $\times 10$).

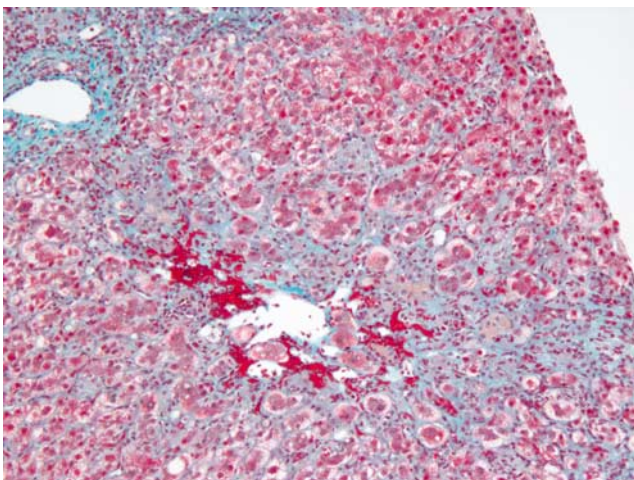


Figure 6 Confluent necrosis (bridging). Large zones of hepatocyte injury and loss are apparent in this trichrome stained tissue. They link the central vein in the middle of the image to the portal tract, upper left, and probably to another portal tract, to the right, but outside of the needle core. These areas of confluent necrosis contain macrophages, mononuclear cells, cellular debris, and, where there is light blue staining, early deposition of collagen (Masson Trichrome, original magnification $\times 10$).

treatment of some other condition) or HIV-related. All of these have great import for the clinical investigation and management of the patient, including dramatic differences in approaches to treatment.

In chronic hepatitis B, confluent necrosis may simply represent a normal stage of disease progression, such as the point of seroconversion from eAg to eAb positive. However, it may also suggest superinfection with delta (hepatitis D),

concomitant drug/toxin mediated injury, or immunocompromise. Given the prevalence of hepatitis B in the intravenous drug using population, these considerations are particularly important. In areas where hepatitis B is endemic, then the possibility of happenstance overlap with other conditions, such as autoimmune hepatitis or, again, immunocompromise, as described with hepatitis C, is also very important to evaluate.

In the absence of confluent necrosis one is left with a range of interface and lobular hepatitis alone. In this era, the relative amounts of these have little clinical impact as treatment decisions are rarely based to even a minor degree on whether the patient has 'mild', or 'moderate' activity. Again, while important for research purposes, which may reveal something clinically important in the future, the obsessive, detailed grading of activity in the absence of confluent necrosis is more of a historic hangover from the Gnomes' original classification.

So in reporting most biopsy specimens, I first look for confluent necrosis. If present, I refer to the activity as severe and suggest the possible clinical implications to be considered. If absent (and confluent necrosis is fairly uncommon, particularly in hepatitis C), I give a rough estimate of the interface and lobular hepatitis (combined) as mild or moderate depending on whether its in the lesser half of what I usually see, and therefore mild, or in the greater half of what I see, and therefore moderate.

In other words, I don't worry about the detail very much. I would probably suggest that one need only actually have three categories of activity: inactive, active without confluent necrosis, active with confluent necrosis. However, clinicians and pathologists are uncomfortable with letting go of more detail about something that has been so obsessively discussed for so many years.

What I Do for Staging

Staging of disease progression is the most important aspect of the routine biopsy for otherwise uncomplicated chronic viral hepatitis. It is this histological feature that most plays a role in the decision of the clinician and the patient about whether to pursue treatment. It is particularly true in this era when the treatments are potentially quite harsh, yet successful eradication is far from guaranteed. In future years, when less harsh or far more successful anti-viral treatments are available, this may change, but for now, clarity and precision about staging is central to the evaluation and treatment of viral hepatitis.

One potentially confusing aspect in the description of scar is whether the earlier stages of scarring are best described as 'portal fibrosis' or 'periportal fibrosis'. Different words are used in different systems. In fact, we still do not truly know if the expansion of stroma in the region of the original

Ishak Staging		Modified Ishak Staging	
No fibrosis	0	No fibrosis	0
Fibrous expansion of some portal areas with or without short fibrous septa	1	Portal fibrosis, with or without short fibrous septa	1
Fibrous expansion of most portal areas, with or without short fibrous septa	2		
Fibrous expansion of most portal areas with occasional portal to portal bridging	3	Fibrous septa	2
Fibrous expansion of portal areas with marked portal-portal and portal-central bridging	4		
Marked bridging with occasional nodules (incomplete cirrhosis)	5	Transition to cirrhosis	3
Cirrhosis, probable or definite	6	Cirrhosis, probable or definite	4

Figure 7 Ishak classification for stage of disease with modification to a 4 point scale.

portal tract in chronic hepatitis is additional collagen deposited *within* the portal tract as a result of portal fibroblast activation, *around* the portal tract resulting from stellate cell activation, or a combination of these two processes. But these issues are too theoretical at this point to belong in a diagnostic report. For simplicity's sake (fewer syllables is better than more syllables), I just use the phrase 'portal fibrosis'.

As my own practice involves both routine diagnostic work as well as clinicopathologic correlations for research and for clinical trials, I have selected the Ishak system for staging of disease progression (Figure 7) For staging in the context of research I use the six point staging system as it is designed. However, I modify it slightly for clinical use, because, as I mentioned above, a six point staging system is too extensive for monitoring of an individual patient's disease state and progression.

For example, the Ishak system distinguishes mild portal fibrosis (stage 2/6) from marked portal fibrosis (stage 3/6). While this is appropriate for large populations of samples and patients, for an individual patient the difference between 1/6 and 2/6 is as likely to be because of tissue sampling as it is to be due to true progression. The same is true for focal fibrous septa (stage 3/6) and frequent fibrous septa (stage 4/6). So, for clinical use, I merge these scores to become 'portal fibrosis (modified Ishak stage 1/4)' and 'fibrous septa (modified Ishak stage 2/4)'. In this manner, the Ishak staging score becomes a four point system like the Scheuer, Batts–Ludwig, and Metavir systems and therefore, has a good expectation for reproducibility.

However, as mentioned above, all of the staging systems have good aspects and less good aspects (there are no inappropriate or bad features in any of them). Selection of a system depends more on

comfort of the pathologist and the needs and expectations of the involved clinicians, that is personal preference. As long as the clinicians understand the nature of the system being used and as long as the pathologist applies it consistently, they all serve the clinical goal of supporting care of the patient.

Caveats Regarding Specimen Adequacy

Can sample size affect accuracy of histologic assessments? Yes. Recent studies suggest a simple and clear answer: a total of 2.0 cm of liver tissue, containing 11–15 portal tracts is necessary to avoid underscoring of stage of disease. Less than that and there are likely to be significant inaccuracies in assessment.^{17–21}

An additional sampling problem concerns small biopsy specimens obtained from the subcapsular region. For perhaps approximately 0.5 cm below the capsule, increased stroma, including septum formation and perhaps even nodularity, may be within the spectrum of normal. Thus, such biopsy specimens may overestimate stage of disease.

It cannot be overemphasized, therefore, that the pathologist must assess samples of tissue provided either by hepatologists or radiologists for *adequacy* before supplying an assessment to the clinician and the patient. It behooves the pathologist to educate their clinical colleagues—radiologists, gastroenterologists, hepatologists—to supply adequate samples, either by obtaining one long needle core or through repeat passes.

It should particularly be made clear to radiologists that they should eschew the easier approach, into the left lobe, for the more traditional right lobe sampling. It appears that the lobes of the liver do not uniformly

progress toward cirrhosis and that sampling of the left lobe may increase the finding of late stage (transition to or fully developed cirrhosis) in a significant number of patients and thus inappropriately influence treatment decisions. Care about not passing too deeply, and thus through, the left lobe may also lead to more sampling of subcapsular tissue.

Writing a diagnosis

Each written diagnosis for an uncomplicated chronic viral (or autoimmune) hepatitis biopsy specimen should contain four pieces of information:

1. The statement that it is, indeed, chronic hepatitis;
2. The grade of activity (including the name of the scoring system used);
3. The stage of activity (including the name of the scoring system used);
4. The known or suspected cause of the hepatitis.

For hepatitis B, the identification of ground glass cells or positive immunostaining for B surface and core antigens allows for definitive statement. Chronic hepatitis C, delta, and autoimmune hepatitis depend on clinical (serologic) information, so these should be stated as 'compatible with...'

The following are examples of how I might compose diagnoses using the different scoring systems. I keep as much histologic detail out of the diagnostic line, keeping it in a descriptive comment, so as to make the important points clear for the clinician and the patient (remember: hepatitis patients, particularly those with hepatitis C, are more and more acting as their own advocates and will often be reading their own reports). For clarity, I also put the most important information, that is staging, into words as well as numbers.

- Chronic hepatitis with Scheuer activity grades 2/4 (portal/periportal) and 1/4 (lobular), stage 3/4 (septa and focal architectural distortion), compatible with hepatitis C.
- Chronic hepatitis B, Metavir grade 1/4 and stage 2/4 (fibrous septa).
- Chronic hepatitis, Batts–Ludwig grade 2/4 and stage 4/4 (cirrhosis), compatible with autoimmune hepatitis.

For my own practice, I avoid the numbers for grading because of the reasons indicated above, so my own diagnostic lines read like this:

- Chronic hepatitis B, mildly active with mild portal fibrosis (modified Ishak stage 1/4).
- Chronic hepatitis, moderately active with transition to cirrhosis (modified Ishak stage 3/4), compatible with hepatitis C.
- Chronic hepatitis, markedly active with confluent necrosis and fibrous septa (modified Ishak stage 2/4), compatible with hepatitis C (see comment).

In this last diagnosis, the 'see comment' is to direct the reader to where I describe the confluent

necrosis (perivenular, bridging necrosis, parenchymal collapse) and make clear that the etiology may be the suggested one, but that other possibilities suggested by the severe activity should be clinically assessed.

Another guideline which deserves particular prominence: *In the setting of concomitant diseases (frequently and notably fatty liver disease) grading and, in particular, staging of changes due to the viral hepatitis may be inappropriate. All scoring systems were created for uncomplicated hepatitis, not for compound disease processes.* This caveat brings us to the final series of points to be made regarding the assessment of chronic viral hepatitis specimens.

Additional features to be routinely assessed

There are, of course, other hepatitis-related features which should be routinely assessed in every chronic hepatitis biopsy specimen, these included hepatitis related changes (hepatitis C-related fat, increased iron uptake, large cell and small cell change) and particularly common concomitant diseases, such as alcoholic and nonalcoholic fatty liver disease and hemochromatosis. It behooves the pathologist to keep these in mind to most completely assess the specimen and serve patient care.

Steatosis

It is well known that hepatitis C, particularly genotype 3, can lead to steatotic change in hepatocytes.²² The trick is in distinguishing this steatosis from true fatty liver disease. In hepatitis C-related fat, the fat is usually mild (<10%) and it is not zonally distributed, as only some of it will be pericentral, as it is in fatty liver disease, but also in the midzone or in periportal locations.

When it is zonal and more extensive, a diagnosis of fatty liver (alcoholic or nonalcoholic) should be made. In that case, full assessment of fatty liver disease, including statement of extent of steatosis, evaluation of steatohepatitis (neutrophilic infiltration, hepatocyte ballooning, Mallory bodies) and steatofibrosis (perivenular, pericellular, and central-portal septa), should be carefully performed. The details of such evaluation are beyond the scope of this paper; however, good reviews have been written elsewhere.^{23–25}

A key point is that if steatohepatitis or steatofibrosis is seen, they imply fatty liver disease, rather than simple hepatitis C-related steatosis. In particular, it is important to watch for steatofibrosis when examining a trichrome stain as even the expert eye may not recognize it on H&E stain. Indeed, given the epidemic nature of nonalcoholic fatty liver disease and the significant prevalence of concomitant (and synergistic) alcoholic liver disease in

hepatitis C patients, it is often necessary to write a second diagnostic line describing this disease process. In this setting, hepatitis scoring may be inappropriate as distinguishing the contributions of each disease may not be reliable. Examples of diagnoses in such settings might look like this:

- Transition to cirrhosis with mixed features of chronic hepatitis C (mildly active) and fatty liver disease (alcoholic vs nonalcoholic) (see comment).
- Cirrhosis with mixed features of chronic hepatitis B (moderately active) and alcoholic liver disease (see comment).
- Frequent fibrous septa with mixed features of chronic hepatitis C (mildly active) and obesity related fatty liver disease (see comment).

Again, the 'see comment' is to direct the reader to a diagnostic comment that evaluates to whatever degree possible, the relationship of each disease to the changes in the specimen. Thus, the presence of a dense mononuclear portal infiltrate, extensive interface and lobular hepatitis, marked portal fibrosis, and portal-portal septa would be considered more likely to be a contribution of the viral hepatitis. On the other hand, perivenular and pericellular fibrosis, central-portal septa, and parenchymal neutrophils may be taken as evidence of fatty liver disease. Both diseases, however, may have some mild degree of portal fibrosis, mild portal mononuclear infiltrates, mild parenchymal lymphocytosis, and focal apoptosis, so these features then can belong to either disease.

Hemosiderosis

Histochemical staining should be routine on every liver biopsy specimen for the screening of hemochromatosis, but it is particularly important in chronic viral hepatitis and, more particularly in chronic hepatitis C.^{23,26} Hepatitis C may itself lead to increased hepatocyte and/or reticulo-endothelial iron stores. This iron is usually, however, mild. There may also be iron related to prior treatment with Ribavirin treatment, which may induce some degree of hemolysis in some patients.

Hereditary hemochromatosis, however, is now known to have quite variable penetrance, so the presence of any iron, even mild, may be evidence of that disease as well.²⁷ Again, how to handle iron-related disease for hemosiderotic liver biopsy specimens is more fully covered elsewhere^{26,28} and later in this journal, but a simple approach might look something like this, in a report:

- Hemosiderosis, grade 1/4, ? hereditary vs secondary hemochromatosis (see comment).

The comment may then include statements such as: 'Prussian blue staining for iron demonstrates hemosiderosis of hepatocytes around some portal tracts. This amount of iron may be related to

hepatitis C infection, however, the small amount does not exclude the possibility of hereditary hemochromatosis due to the variable penetrance of this disease. Clinical correlation (genetic testing) may be helpful'. Some clinicians may even prescribe venopuncture for some patients to reduce hepatocyte iron as it is thought by some to improve the likelihood of viral clearance with treatment.

Purely reticuloendothelial iron does not suggest hereditary hemochromatosis and is more likely a reflection of hemolysis (perhaps Ribavirin-induced or due to other unrelated causes).²⁹ Also, in patients with fully established cirrhosis, the cirrhosis itself may lead to increased iron uptake from the gut and, then, hemosiderosis of the liver. Thus, when there is clear cirrhosis and iron I make this suggestion first in the companion comment.

Neoplasia-Related Changes

Both hepatitis C and hepatitis B dramatically increase the risk for hepatocellular carcinoma. Cellular atypia that may suggest early or incipient neoplasia may be recognized in biopsy specimens, though, as with most pathology, if one doesn't specifically think to look for it, it may go unnoticed.³⁰ These changes were previously referred to as 'dysplasia', but for reasons beyond the scope of this paper, are now referred to as 'change', as in 'large cell change' and 'small cell change'.³¹

Large cell change is now generally thought to be malignancy associated, rather than directly premalignant. Nonetheless, its presence is thought by many to indicate a patient with further increased risk for development of hepatocellular carcinoma who may benefit from more rigorous cancer surveillance, though the need to report it is still not settled and may be dependent on the background liver disease.^{32,33} This cellular change is characterized by often large, atypical nuclei (often reflecting aneuploidy), multinucleation, and abundant cytoplasm. (Figure 8). Thus, there is a fairly normal nuclear:cytoplasmic ratio. The cells are not generally in nodular array, but instead are intermixed with normally sized, regenerating hepatocytes, often in periportal or periseptal locations.

Small cell change, on the other hand, is thought to be directly premalignant.^{30,34} It consists of small hepatocytes, with relatively normal size, but hyperchromatic, often grooved or irregular nuclei (Figure 9). These, therefore, have an increased nuclear:cytoplasmic ratio. Cytoplasm often has a bluish appearance on H&E stain. These cells are usually in clustered arrays if not actually forming clear subnodules. Reticulin stain may highlight such nodularity and also demonstrate slight loss of reticular fibers.

It is also becoming increasingly recognized that these pre-malignant or malignancy associated changes (indeed, even carcinoma itself) may pre-

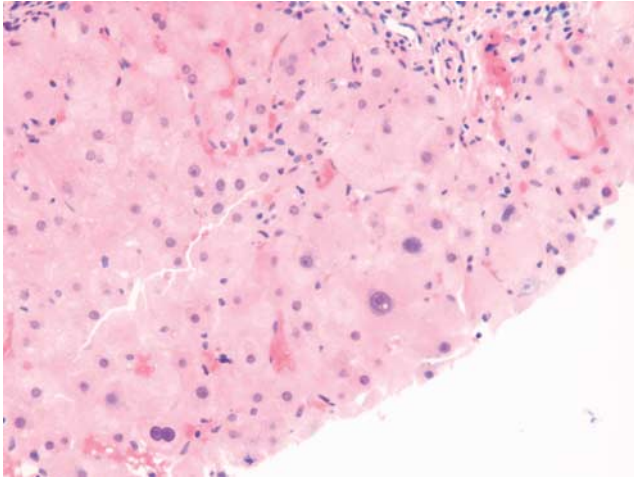


Figure 8 Large cell change. Large hepatocytes are easily seen scattered among the normal size, regenerating hepatocytes. They are large cells with large, often hyperchromatic and atypical appearing nuclei. Multinucleation may be common. Despite their 'dysplastic' appearance, they have a relatively normal nuclear:cytoplasmic ratio (H&E, original magnification $\times 20$).

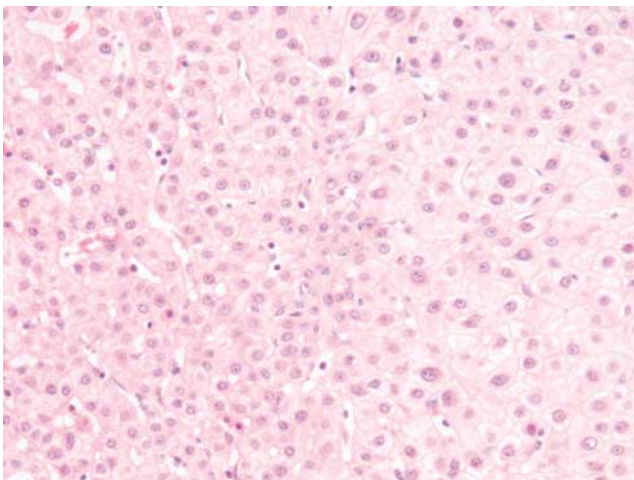


Figure 9 Small cell change. Small hepatocytes in the center and left of the image have slightly smaller nuclei than normal hepatocytes on the right side, but their cytoplasm is considerably reduced resulting in a markedly increased nuclear to cytoplasmic ratio. Their cytoplasm may also be somewhat basophilic. Trabeculae of hepatocytes with small cell change are often thick or difficult to discern yielding a 'cobblestone' appearance. Such cells may form tight subnodules or their clustering may be a little less well defined, as seen here, though they are not found scattered individually the way hepatocytes with large cell change often are (H&E, original magnification $\times 20$).

cede the development of cirrhosis. In other words, just because the patient does not have cirrhosis does not mean that these features are absent or that the patient may not be at risk for malignancy. The concept that cirrhosis itself is premalignant is probably incorrect; rather, it develops in parallel with neoplasia in a chronically diseased liver.^{35,36}

Coinfection with HIV

During the early years of hepatitis C recognition, there was also very little that could yet be done for HIV infection. Successful anti-retroviral therapy was still more than half a decade away. Hepatitis C in this setting was generally found to be worse, both with greater severity of activity and more rapidly advancing fibrosis. Subsequent to successful long-term maintenance of immune competence, this expectation of worse or more rapid injury are not necessarily reflected by the biopsy specimens that now come before from patients with coinfection.^{23,26} Thus, in patients who are stable with competent immune systems, the findings in liver biopsy specimens for hepatitis C or B require no different treatment than those from non-HIV infected patients. On the other hand, if the patient is not immune competent, then one may see more severe disease (including confluent necrosis or rapid progression toward cirrhosis). In addition, in such patients, one must also keep an eye open for all the 'old' lesions: granulomas, infectious organisms (with examination of special stains for fungi and acid fast organisms), and infiltrating neoplasms.

In summary

This era of diagnosis and treatment of chronic viral hepatitis is full of great clinical possibility, rapidly advancing past the early decades of the field when nothing but description, watching and waiting was available. But, like any transitional period, these opportunities come with some measure of confusion, even for those with extensive experience, even expertise. It is my hope that this text might help cut through that 'scoring jungle' for the general pathologists who do not have the time to wade through detailed reviews and theoretical speculations. However, my choices and opinions (except, perhaps, the three statements printed in italics within the text) are not the 'correct' ones; we must each make our own selections from the options available. As I hopefully have shown, the task is not, in fact, particularly daunting. With the example of the Gnomes who came before us, a methodical and rational consideration of histologic findings and the relevant clinical correlates can lead to clear and consistent descriptions of benefit to our clinicians and to our patients.

Acknowledgements

There is little in the way of research, teaching, or writing in my career in hepatopathology that I would have accomplished, if it weren't for the mentoring I received from Peter J Scheuer, my teacher, my colleague, my friend, my 'professional father' as he sometimes said. Indeed, for the many hepatopathologists for whom he played that role of

professional father, his influence continues to expand outward, even after his death earlier this year. He will be remembered fondly for his caring, but he will be continually honored by our labors, in the service of our patients, to correctly and carefully diagnose our liver biopsy specimens, holding ourselves to the rigorous standards he set for his own practice.

Many thanks to Ken Batts for permission to reproduce the figures from his original paper here and to Linda Ferrell for her patience and guidance in the final organization of this manuscript.

References

- De Groote J, Desmet VJ, Gedigk P, *et al.* A classification of chronic hepatitis. *Lancet* 1968;2:626–628.
- Scheuer PJ. The nomenclature of chronic hepatitis: time for a change. *J Hepatol* 1995;22:112–114.
- Gerber M. Chronic hepatitis C: the beginning of the end of a time-honored nomenclature? *Hepatology* 1992;15:733–734.
- Hunt N, Fleming K. Reproducibility of liver biopsy grading and staging. *Liver* 1999;19:169–170.
- Brunt EM. Grading and staging the histopathological lesions of chronic hepatitis: the Knodell histology activity index and beyond. *Hepatology* 2000;31:241–246.
- Scheuer PJ, Standish RA, Dhillon AP. Scoring of chronic hepatitis. *Clin Liver Dis* 2002;6:335–347.
- Koukoulis G. Chronic hepatitis C: grading, staging, and searching for reliable predictors of outcome. *Hum Pathol* 2001;32:899–903.
- Desmet VJ. Histological classification of chronic hepatitis. *Acta Gastroenterol Belg* 1997;60:259–267.
- Ferrell L. Histological classification of chronic hepatitis. *Acta Gastroenterol Belg* 1997;60:259–267.
- Ishak K, Baptista A, Bianchi L, *et al.* Histological grading and staging of chronic hepatitis. *J Hepatol* 1995;22:696–699.
- Desmet VJ, Gerber M, Hoofnagle JH, *et al.* Classification of chronic hepatitis: diagnosis, grading and staging. *Hepatology* 1994;19:1513–1520.
- Knodell RG, Ishak KG, Black WC, *et al.* Formulation and application of a numerical scoring system for assessing histological activity in asymptomatic chronic active hepatitis. *Hepatology* 1981;1:431–435.
- Scheuer PJ. Classification of viral hepatitis: a need for reassessment. *J Hepatol* 1991;13:372–374.
- Bedossa P, Bioulac-Sage P, Callard P, *et al.* Intra-observer and interobserver variations in liver biopsy interpretation in patients with chronic hepatitis C. *Hepatology* 1994;20:15–20.
- Batts KP, Ludwig J. Chronic hepatitis. An update on terminology and reporting. *Am J Surg Pathol* 1995;19:1409–1417.
- Theise ND, Bodenheimer H, Ferrell L. Viral hepatitis. In: Burt A, Portmann B, Ferrell L (eds). *MacSween's Pathology of the Liver*, 5th edn. Churchill Livingstone/Elsevier: London, UK, 2006 (in press).
- Guido M, Rugge M. Liver biopsy sampling in chronic viral hepatitis. *Semin Liver Dis* 2004;24:89–97.
- Fanning L, Loane J, Kenny-Walsh E, *et al.* Tissue viral load variability in chronic hepatitis C. *Am J Gastroenterol* 2001;96:3384–3389.
- Regev A, Berho M, Jeffers LJ, *et al.* Sampling error and intraobserver variation in liver biopsy in patients with chronic HCV infection. *Am J Gastroenterol* 2002;97:2614–2618.
- Persico M, Palmentieri B, Vecchione R, *et al.* Diagnosis of chronic liver disease: reproducibility and validation of liver biopsy. *Am J Gastroenterol* 2002;97:491–492.
- Siddique I, El-Naga HA, Madda JP, *et al.* Sampling variability on percutaneous liver biopsy in patients with chronic hepatitis C virus infection. *Scand J Gastroenterol* 2003;38:427–432.
- Zekry A, McHutchison JG, Diehl AM. Insulin resistance and steatosis in hepatitis C virus infection. *Gut* 2005;54:903–906.
- Lefkowitz JH. Hepatobiliary pathology. *Curr Opin Gastroenterol* 2006;22:198–208.
- Farrell GC, Larter CZ. Nonalcoholic fatty liver disease: from steatosis to cirrhosis. *Hepatology* 2006;43(2 Suppl 1):S99–S112.
- Brunt EM. Nonalcoholic steatohepatitis. *Semin Liver Dis* 2004;24:3–20.
- Alla V, Bonkovsky HL. Iron in nonhemochromatotic liver disorders. *Semin Liver Dis* 2005;25:461–472.
- Gattoni A, Parlato A, Vangieri B, *et al.* Role of hemochromatosis genes in chronic hepatitis C. *Clin Ther* 2006;157:61–68.
- Brunt EM. Pathology of hepatic iron overload. *Semin Liver Dis* 2005;25:392–401.
- Fiel MI, Schiano TD, Guido M, *et al.* Increased hepatic iron deposition resulting from treatment of chronic hepatitis C with ribavirin. *Am J Clin Pathol* 2000;113:35–39.
- Libbrecht L, Desmet V, Roskams T. Preneoplastic lesions in human hepatocarcinogenesis. *Liver Int* 2005;25:16–27.
- Wanless I, Callea R, Craig JR, *et al.* Terminology of nodular lesions of the liver: Recommendations of the World Congress of Gastroenterology Working Group. *Hepatology* 1995;22:983–993.
- Borzio M, Bruno S, Roncalli M, *et al.* Liver cell dysplasia is a major risk factor for hepatocellular carcinoma in cirrhosis—a prospective study. *Gastroenterology* 1995;108:812–817.
- Ganne-Carrie N, Chastang C, Chapel F, *et al.* Predictive score for the development of hepatocellular carcinoma and additional value of liver large cell dysplasia in western patients with cirrhosis. *Hepatology* 1996;23:1112–1118.
- Marchio A, Terris B, Meddeb M, *et al.* Chromosomal abnormalities in liver cell dysplasia detected by comparative genomic hybridisation. *J Clin Pathol-Mol Pathol* 2001;54:270–274.
- Theise ND. Cirrhosis and hepatocellular neoplasia: More like cousins than like parent and child. *Gastroenterology* 1996;111:526–528.
- Vallet-Pichard A, Pol S. Natural history and predictors of severity of chronic hepatitis C virus (HCV) and human immunodeficiency virus (HIV) co-infection. *J Hepatol* 2006;44(1 Suppl):S28–S34.